



Electroencephalography (EEG)

The EEG is the most informative laboratory test in individuals with epileptic seizures. It may play an important role in the diagnosis of epilepsy, classification of the type of epileptic seizure and epileptic syndrome, determining the area in the brain where seizures begin and in certain instances may influence the choice of anti-epileptic medication.

The diagnosis of epilepsy is usually based on the history. Due to the random and often unpredictable nature of epileptic seizures, the EEG is typically recorded between seizures and conclusions are based on the EEG findings in between seizures. If the area triggering seizures lies deep within the brain, such as in the frontal or temporal lobes, the EEG recording may be normal. Indeed, even repeated EEGs may be normal in some patients with epilepsy. In contrast epileptiform EEG patterns occur in about one to two percent of patients without any history of epileptic seizures. Relatives of individuals who have epilepsy may have inherited genetic EEG patterns and not have any epileptic seizures. Thus it is important the EEG findings are interpreted correctly and correlated with the patient's clinical history.

Technical Aspects of EEG

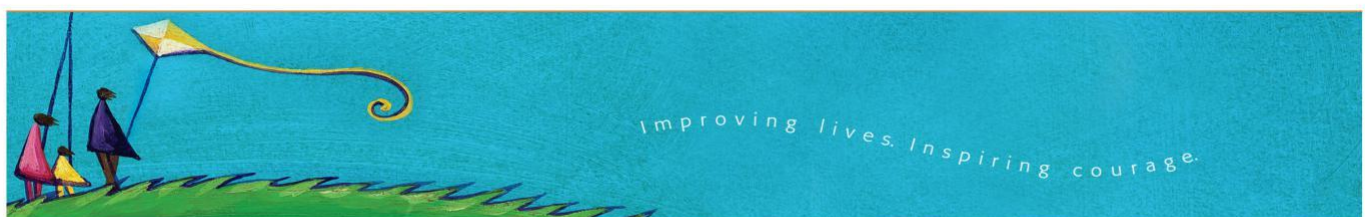
The EEG measures the difference in electrical potential between two points on the surface of the head. It is a tracing of the voltage fluctuations over time recorded from electrodes placed over the scalp in a specific manner. This represents fluctuating electrical potentials in membranes of neurons (brain cells) in superficial layers of the brain cortex. The skull, scalp, and cerebrospinal fluid reduce the EEG activity that is detected on the surface of the scalp.

Typically, 19 EEG electrodes are placed over the scalp as well as electrodes that are reference electrodes placed over the ears, cheek, and to pick up the electrocardiogram (ECG). In selective situations the neurologist may suggest that additional electrodes be applied in order to record the EEG activity that may be missed by a routine EEG.

Activation Procedures During an EEG

Activation procedures are performed in order to induce or bring out EEG abnormalities that may not be present on routine EEG recording.

Hyperventilation is a procedure in which the patient is asked to breathe deeply for three to four minutes. This procedure particularly tends to influence absence seizures that have a classical EEG pattern referred to as three-second spike and wave discharges. Absence seizures tend to occur more prominently in children than in adults.



Intermittent photic stimulation using a strobe light is an activator of spike wave or polyspike wave discharges that tend to occur more typically in certain genetic forms of epilepsy or myoclonic epilepsy. This phenomenon is referred to as photosensitivity or a photoparoxysmal response.

Sleep Deprived EEG Recording

The patient stays up late the night before the EEG and gets up very early in the morning that usually allows the patient to sleep during the EEG recording and in certain types of epilepsy, EEG abnormalities may appear only in sleep.

Video-EEG Monitoring and Ambulatory EEG Recordings

Video-EEG monitoring allows simultaneous recording of the EEG and video data and is of particular value in assessing patients for epilepsy surgery and determining whether clinical events the patient is experiencing are epileptic or not epileptic in nature.

In some EEG laboratories such as BC Children's Hospital video recordings have been performed as part of routine EEG recordings over the past 10 years. This is not standard practice in all laboratories.

Ambulatory EEG allows continuous EEG monitoring during normal activities and can be helpful in assessment of seizure frequency and determination of the nature of clinical behaviours. Patients are able to walk around and leave the hospital with the EEG recordings on and typically the battery allows continuous EEG recording for 18 to 24 hours.

Invasive Video-EEG Monitoring

This involves placement of electrodes directly on (subdural grid or strip electrodes) or within (depth electrodes) the brain surface and is performed in patients undergoing brain epilepsy surgery in select situations.

Approved for circulation in January 2009 (lh)

You can join the BC Epilepsy Society as a member and receive all the program and service benefits.

#610 – 4180 Lougheed Highway, Burnaby, BC V5C 4B3

Phone: (604) 875-6704 Fax: (604) 875-0617 info@bcepilepsy.com www.bcepilepsy.com