



## Epilepsy Surgery

Traditionally, surgery has been considered a treatment of last resort. However, this is untrue and surgery may dramatically reduce or control seizures in carefully selected patients. Surgery is an under-utilized treatment for epilepsy in both adults and children.

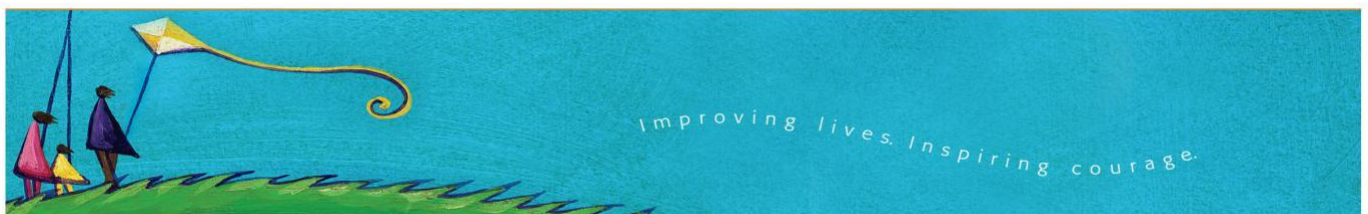
### What is epilepsy surgery?

It involves an operation that is aimed to reduced or control seizures. There are many types of surgical procedures that can be performed. Most commonly it involves removal (resection) of an area of the brain (focal cortical resection) that triggers seizures. If the surgery involves removal of an entire lobe of the brain the term used is lobectomy. If the area of the brain causing seizures is extensive involving more than one lobe of the brain or one side of the brain (hemisphere) a more extensive operation may be performed called multilobar resection or hemispherectomy. A hemispherectomy involves disconnection of one side of the brain (functional hemispherectomy), or removal of an extensive area of cortex of one side of the brain (hemidecortication), or in some rare instances complete removal of one hemisphere (anatomic hemispherectomy). In most centres in Canada where epilepsy surgery is performed, functional hemispherectomy is the procedure of choice for hemispheric surgery. In the adult population, anterior medial temporal lobectomy is the most common surgery performed. In patients who have seizures arising from multiple areas of the brain, and particularly patients who fall without warning during seizures, a palliative operation disconnecting the left from the right hemisphere may be performed called a corpus callostomy. The operation may involve disconnection of the anterior two thirds of the corpus callosum or the entire corpus callosum called a complete corpus callostomy.

If seizures arise in an important area of the brain such as the area controlling language or hand function it is not possible to re-sect these areas and a procedure called multiple subpial transactions (MSTs) may be performed. This interrupts the pathway for spread of electrical seizure activity but not for function so that this type of surgery is not associated with loss of language or hand function.

### Which patients are suitable for epilepsy surgery?

Typically patients who are suitable for resection of an area of the brain have seizures that arise in one area of the brain and this area can be safely removed without causing the patient major problems. It is important that a patient is carefully evaluated by a neurologist who has special training in epilepsy and epilepsy surgery. In BC there are programs for epilepsy surgery in children at BC Children's Hospital and the Vancouver Hospital for adults. In most instances, the evaluation involves video-EEG monitoring where the patient is admitted to hospital for several days in order to record typical seizures so that the neurologist can assess where in the brain the seizures begin. High-resolution magnetic resonance imaging (MRI) is an important investigation and this allows one to look at brain structure in detail. Neuropsychological assessment by a neuropsychologist with experience in epilepsy involves detailed assessment of brain function such as language, memory, attention, and other tasks. The investigation for epilepsy surgery also involves consultation with a psychiatrist, as there is



a higher risk of depression, anxiety, and other psychiatric disorders in individuals with epilepsy. In some instances if these initial investigations are not conclusive, the neurologist suggests other investigations such as single photon emission computed tomography (SPECT) scanning during and in between seizures and this is another tool that helps identify the region of the brain where seizures originate. Positron emission computer tomography (PET) is also used in selected patients. Functional MRI, where one can assess hemisphere dominance for language and the location within that hemisphere the location of language pathways, the area controlling hand function, and the visual pathway, may be necessary in some patients. Sodium amytal (WADA) testing may be necessary if there is a risk to memory with surgery. After the evaluation the epilepsy surgery team meets to discuss the findings and what is the best surgical approach. In the majority of patients, surgery is planned in stage one.

In about 20% of patients it may not be possible to proceed with surgery at this time. In this group, it may be necessary to perform invasive EEG monitoring using subdural grid or depth EEG electrodes. This involves placement of EEG electrodes on in brain tissue in order to precisely locate the area of the brain triggering seizures.

What are the risks associated with epilepsy surgery?

Every medical and surgical treatment is associated with the potential to cause side effects. Each patient is different and in each patient the benefit/risk ratio needs to be assessed. Medically refractory epilepsy is associated with ongoing risks of morbidity and mortality and one must balance risks associated with surgery with the risks associated with poorly controlled epilepsy if one continues with medications.

There are general risks that may occur with any type of surgery such as a complication of anesthesia, bleeding, and infection. To minimize risks associated with blood transfusion, it may be possible for the patient to donate their own blood (autologous blood transfusion). Infection complicating brain surgery includes risk of meningitis (infection of the meninges that are layers of membrane that cover the brain). Brain swelling may occur after surgery and this may be associated with headache, low sodium in the blood, and irritability. The surgeon may prescribe medication to reduce the risk of swelling after surgery. Rarely, the surgeon may accidentally damage a blood vessel and this could result in a stroke. There are also risks of epilepsy surgery that are specific to each patient based on the area of the brain that is resected. For example, temporal lobe resection is one of the most common types of epilepsy surgery performed and there is a risk of deterioration of memory following surgery. If the visual field pathway is included in the area of the resection, the patient may have a visual field defect that may involve a small area, a quadrant, or half of the visual field (hemianopia). If surgery is performed in the area of the brain that controls language or hand function, these functions may be impaired post-surgery. In general, removal of an area of the brain that is important in the control of speech or hand function is not performed unless the risks associated with the seizures is so great that the potential benefit of a reduction in seizures outweighs the risks. In young children, the area of the brain controlling speech may be removed and language may transfer to the opposite hemisphere or side of the brain. There is also a risk of depression and rarely psychosis following certain types of epilepsy surgery and some individuals may have a genetic predisposition to develop psychiatric illness.

How soon will I know that surgery has been effective?

Seizures that occur in the first few weeks or months following surgery do not necessarily mean that the surgery has been unsuccessful. If seizures continue after three to six months following surgery, it's likely that the operation has not been completely successful. Over time there is a risk of seizure recurrence many years following surgery and this is more likely to occur if the cause of the epilepsy is a disorder of brain development such as cortical dysplasia.

Who should I contact in BC for evaluation for epilepsy surgery?

There are epilepsy surgery programs at the Vancouver General Hospital and BC Children's Hospital.

Approved for circulation in April 2009 (mc/lh)

You can join the BC Epilepsy Society as a member and receive all the program and service benefits.

#610 – 4180 Lougheed Hwy, Burnaby, BC V5C 4B3

Phone: (604) 875-6704 | Fax: (604) 875-0617 | [info@bcepilepsy.com](mailto:info@bcepilepsy.com) | [www.bcepilepsy.com](http://www.bcepilepsy.com)